

The analysis of visual outcome and complications in camp patients undergoing manual small incision cataract surgery during COVID-19 period

Rekha R. Mudhol^{1*}, Piyushi Sao¹, Rikita R Mudhol², Sunil Biradar¹, Vallabha K¹, Raghavendra Ijeri¹ and Nikhita Sankolli¹

¹Department of Ophthalmology, Shri B.M. Patil Medical College, Hospital and Research Centre, Bangaramma Sajjan Campus, Solapur Road, Vijayapura-586103, Karnataka, India and ²Department of General Medicine, SDM College of Medical Sciences and Hospital, Shri Dharmasthala Manjunatheshwara University, Manjushree Nagar, Dharwad-580009, Karnataka, India

Received: 08th August 2023; **Accepted:** 11th December 2023; **Published:** 01st January 2024

Abstract: *Objectives:* To analyse the visual outcomes and determine the manual small incision cataract surgery (MSICS) complications in camp patients during the Covid-19 period. *Methods and Analysis:* It is a retrospective cross-sectional study conducted at a tertiary hospital in South India. 988 camp patients who underwent MSICS over one year. The study comprised of cataracts with diabetes mellitus, senile mature cataracts, immature cataracts, hypermature cataracts, pseudoexfoliative cataracts, and senile mature cataracts. All patients underwent MSICS. OCTET standards were used to grade the post operative complication and BCVA was assessed on days 1, 7, 4th week, and 6th week after surgery. *Results:* According to the WHO grading of visual outcome post cataract surgery, 97.4% (n=962) cases had a good visual outcome. Mild iridocyclitis was the most common post-operative day 1 complication, 24.3 % (n=240). After four weeks post-surgical intervention, the major complication was posterior capsular opacity of 3% (n=30). *Conclusion:* We can achieve minimal risk of intra-operative and post-operative complications with a favourable visual outcome by conducting similar screening camps and performing Manual small incision cataract surgery to manage high volume cataract cases post COVID 19 period.

Keywords: Cataract, Pandemic, Visual Acuity, Uvietis.

Introduction

Cataracts and refractive errors are two critical public health issues in underdeveloped countries like India regarding ocular health. India is second in contributing to the global burden of blindness [1]. According to the National Blindness & Visual Impairment Survey 2015-2019, 66.2% of blindness was caused by cataracts, followed by corneal opacity (7.4%), 7.2% were caused by complications post cataract surgery, disorders of the posterior segment (5.9%), and Glaucoma (5.5%). It is noteworthy that blindness due to cataract surgical complications has increased from 1.5% (2002) to 7.2% (2019) [2].

In our haste to meet unrealistic standards, we must not make mistakes merely causing curable blindness into a complication leading to incurable blindness. While the enormity of cataracts in our country necessitates a high volume of eye

surgeries, there is a need to improve cataract surgery quality through better case selection and post-operative care. The National Programme for Control of Blindness (NPCB) aims to clear the piled-up cataract cases by conducting free camps [3]. Manual small incision cataract surgery (MSICS) is a commonly employed technique in such conditions. MSICS is less arduous to perform and is more cost-efficient than phacoemulsification. It is the most suitable method for managing high-volume cataract surgeries in developing countries [4]. During the COVID-19 pandemic, eye camps in India were affected. The entire country had closed all elective medical care services with much uncertainty.

Because of the lockdown-related constraints, many ophthalmology institutes were operating

on a significantly smaller scale than usual. Delays in visiting the hospital due to lockdown and fear of infection might lead to the cataract getting more pronounced, which makes the intraoperative challenges severe. A number of elderly patients were reluctant to visit the hospital due to their fear of contracting COVID-19. The prolonged waiting period frequently led to the emergence of advanced cataracts (lockdown cataracts) [5-7]. As a result, the current study aims to assess the complications and visual outcomes of MSICS in camp patients [8], in addition to the challenges faced during the Covid-19 period.

Material and Methods

This is a retrospective cross-sectional study conducted in a tertiary hospital in Karnataka from January 2021 to December 2021. Ethical clearance was obtained from the institutional ethical review board. This study included data collected from the records of patients above 40 years of age who were managed with manual small incision cataract surgery (MSICS) during the study period. These cases were screened in community-based camps (nine primary health centres in and around Vijayapur) and transferred to the tertiary care Centre. A brief history, torch-light examination, fundus examination, intraocular pressure (IOP) measurement, and sac syringing were performed at the camps. The Primary health centre undertook basic systemic assessment, blood pressure, urine sugar estimation and RT-PCR for COVID-19. All selected patients were reviewed and advised as per COVID-19 protocol by physician. A preoperative examination was performed as per protocol after admission to a tertiary hospital. Lens Opacification Classification System II (LOCS II) is used to type and grading of lens opacities.

Direct/indirect ophthalmoscopy was used to evaluate the posterior segment and retina thoroughly. Goldmann's applanation tonometer was used to measure IOP. Keratometry and A-scan biometry were used to calculate IOL power for all patients. Xylocaine sensitivity, random blood sugar, HbsAg and HIV serology were tested in all admitted patients. Preoperatively, topical antibiotics were instilled, and pupils were dilated using tropicamide eye drops. Manual small incision cataract surgery was performed. Postoperatively, oral analgesics and antibiotics

were prescribed, and topical steroids with antibiotics were tapered. They were tested for vision and evaluated for complications according to Oxford Cataract Treatment and Evaluation Team (OCTET) guidelines [7, 9] on post-operative day 1, day7, 4th week, and 6th week including.

- *Grade I:* Minor issues that necessitate medical attention but are not anticipated to significantly impair vision.
- *Grade II:* Includes Intermediate problems that necessitate medical attention and, if untreated, will significantly reduce visual acuity.
- *Grade III:* Includes significant side effects that necessitate rapid surgical or medical intervention to prevent irreversible visual loss [7-8].

The visual outcome post cataract surgery was categorised by the WHO standards, categorising visual impairment into 3 major categories.

- Normal to slight visual impairment from 6/6 to 6/18
- Moderate visual impairment from 6/18 to 6/60.
- <6/60 - > severe visual impairment (3/60) [9-10].

The study comprised cataracts with diabetes mellitus, senile mature cataracts, immature cataracts, hypermature cataracts, pseudoexfoliative cataracts, and senile mature cataracts. Congenital cataracts, complicated cataracts, other ocular defects, cataracts brought on by trauma, cataracts linked to retinal illnesses, complicated cataracts, and patients unable to keep their post-operative follow-up sessions were also excluded from the study.

Data analysis: A statistical tool for the social sciences (Version 20) was used to conduct statistical analysis after the data were carefully entered into a Microsoft Excel sheet.

- The results were shown as mean, standard deviation, frequency, percentages, and graphs.
- For the purpose of comparing categorical variables between two groups, the marginal homogeneity test was used.
- Statistics were deemed significant at $p < 0.05$.

- Two-tailed statistical tests were used for all analyses.

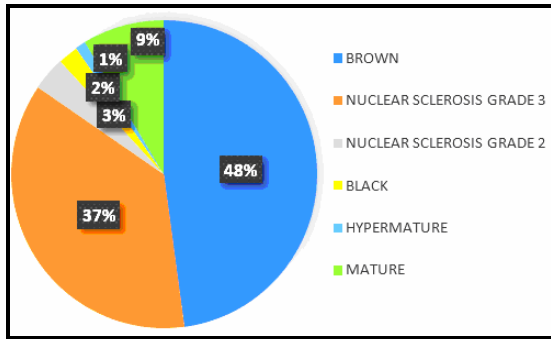
Results

There were 988 patients, out of which 49.8 % (n=492) were 61-70 years old (Table 1). Among 988 patients 43.2 % (n=427) were males, and 56.8 % (n=561) were female. Cataract grading was done according to the LOCSII system, as shown in (Figure 1). The majority were Brown Cataracts, followed by 1% (n=10) cases of pseudoexfoliation cataracts. The mean Intraocular Lens power was 21.28D (±1.85). The mean intraocular pressure across the study group was 11.42 mmHg (±1.57).

Table-1: Age distribution of the cases enrolled in the study

Range	Frequency	Percentage
<=50	48	4.9%
51-60	215	21.8%
61-70	492	49.8%
71-80	205	20.7%
81+	28	2.8%
Total	988	100.0%

Fig-1: Types of cataract encountered during the study



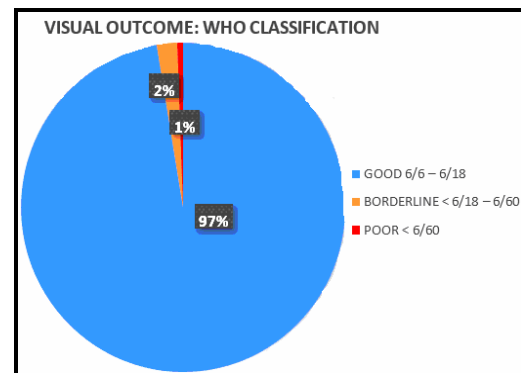
Intraoperative complications included 1% (n=10) posterior capsular rupture and 1% (n=10) Descemet's detachment. The posterior capsular rent was managed by scleral fixated posterior chamber intraocular lens, and descemet's membrane detachment was managed by intracameral air bubble tamponade. On postoperative day one, 24.89 % (n=246) of cases had grade I complications, 2% (n=20) belonged to grade II, and 1% (n=10) were included in grade III complications, as per (OCTET) criteria (7), with 24.3 % (n=240) mild iritis (Table 2), followed by corneal oedema 20.3% (n=200) and striate keratopathy 12.1% (n=120).

Table-2: Octet grading of the post-operative complications encountered in the study

Grade –I	No of cases (Percentage)
Mild Iritis < 50 cells in 2*1mm Slit	240 (24.3%)
Transient Corneal Edema	200 (20.2%)
Striate Keratopathy	120 (12.1%)
Subconjunctival Hemorrhage	10 (1%)
Grade-II	
Severe Iritis >50 Cells in 2*1mm Slit beam	20 (2%)
Iris in wound	10 (1%)
Shallow AC	4 (0.4%)
Grade-III	
Descemet's Detachment	10 (1%)

After four weeks of surgery, the most common post-operative complications were posterior capsular opacity 3% (n=30) and pigment on PCIOL 1% (n=10). According to the WHO grading of visual outcome of cataract surgery, 97.4% (n=962) cases had a good outcome, 2% (n=20) had borderline outcome, and 0.6% (n=6) had a poor outcome at four weeks duration in this study (Figure 2).

Fig-2: Visual outcomes of patients post manual small incision cataract surgery



Discussion

Cataract procedures have been disrupted by the COVID-19 pandemic, so a plan for safe surgical protocol throughout the COVID-19 time needs to be developed [11]. The predominant patients included in this study were in the range 61-70years. This was very analogous to previous studies done in the non-COVID 19 periods, with the mean of 63+/- 10 years in the Wetarini et al. Study [12] and 61-70 years in the study by Khandekar in central

India [13]. Our study found more women (56.8%) to have cataracts. Previous research has shown that women are more likely than men to get cataracts. This may be because males typically live shorter lives than women, which increases the likelihood that they may need cataract surgery [13].

The prevalence of viral seropositivity increased among patients who planned for cataract surgery in a study by Mishra et al [14]. All patients underwent workup for viral markers Hepatitis B surface antigen (HBsAg) and HIV. Still, particular emphasis was put on RT-PCR testing for COVID-19. All study subjects were COVID-19 Negative on RT-PCR. The pandemic made it easier to persuade patients, caregivers, and healthcare providers of the relevance of viral seropositivity and the benefits of testing. The majority of patients during this study period had Severe Visual Impairment (SVI), defined as having visual acuity between 6/60 and 3/60 in the better eye at presentation, as opposed to Early Visual Impairment (EVI), defined as having visual acuity between 6/12 and 6/18 in the better eye at presentation. During the Covid-19 second wave corresponding to this study period, people were cautious of hospitals and avoided visits until they were absolutely debilitating. As shown in (Figure 1), 48% of patients had cataracta brunescens; while it points towards a geographic predisposition, there is also a factor of the longstanding duration of cataracts. There was an overall prevalence of mature, hyper-mature cataracts, leading to increased intraoperative complications.

In a study by Murallikrishnan et al., the proportion of out-patients with impaired eye vision of less than 5/60 or who required referral was much higher during the second wave [15]. This study had 3.4% (n=34) intraoperative complications, with 1% (n=10) PCR linked with hyper mature and pseudoexfoliated cataracts in a study by Segers et al [16]. Corneal opacities, low preoperative visual acuity, and white cataract were the risk factors most substantially linked with PCR. Most complications on post-operative day one were grade 1 as per the OCTET guidelines [13]. These complications like corneal edema, mild iritis, and striate keratopathy resolve within a week after appropriate treatment, improving visual acuity. Grade III complications

that require further intervention were mainly Descemet's detachment and were taken for air bubble injection. Most cases of hypermature cataract had severe iritis on post-operative day one. This may be due to an alteration or loss of immune tolerance to lens proteins and the Anterior chamber-associated immune deviation (ACAID) leading to severe uveitis in advanced cataract [17].

While there were 1% (n=10) cases with an old macular scar and mature cataract, which account for Hand movement vision on day one, these cases were included in the study as the preoperative detailed retinal exam was not possible due to hazy media. Few patients presented with iris incarceration in the surgical wound after a week; these cases had an incident of trauma or were simply non-compliant and rubbed their eyes. Overall there was a 97% good visual outcome despite a vast majority of mature and complicated cataract in this study thanks to meticulous screening, aseptic precautions, skilled surgeons, post-operative care, and regular follow-up. Contradictory to other studies where such results were obtainable through phacoemulsification, this study proves that even high volume MSICS at a tertiary centre can provide satiable outcomes. A consistent presence in one area fosters an appreciation for the quality of services and enables community engagement [18-20].

Conclusion

COVID 19 has created a large backlog of cataract cases that requires immediate and effective management, this study accounted the severity of visual impairment in camp patients during this period and successfully managed them by performing MSICS, thus can be used as a preferred procedure in managing high volume cataract cases with favourable visual outcome and minimal intraoperative and post operative complication.

Acknowledgements

We thanks to BLDE (Deemed to be University) Shri B.M. Patil Medical College, Hospital and Research Centre, Vijayapura for providing us a platform to conduct this study.

Financial Support and sponsorship: Nil

Conflicts of interest: There are no conflicts of interest.

References

1. Senjan S. Outcome of Cataract Surgery from Outreach Eye Camp. *Delhi J Ophthalmol.* 2014; 25(2):90-94.
2. Ministry of Health & Family Welfare Government of India. The National Blindness and Visual Impairment Survey 2015-2019- A Summary Report. *Natl Progr Control Blind Vis Impair.* 2019; 1-15.
3. Verma R, Khanna P, Prinja S, Rajput M, Arora V. The national programme for control of blindness in India. *The Australasian Medical Journal.* 2011; 4(1):1.
4. Singh K, Misbah A, Saluja P, Singh AK. Review of manual small-incision cataract surgery. *Indian Journal of Ophthalmology.* 2017; 65(12):1281-1288.
5. Pandey SK, Sharma V. Commentary: Improving the cataract surgery efficiency and clearing the cataract surgery backlog due to COVID-19 pandemic. *Indian Journal of Ophthalmology.* 2021; 69(12):3651.
6. Bhalerao S, Majji S, Mohamed A, Vuyuru S, Gogri P, Garg P. Changing trend in the morphology of cataracts at a tertiary eye care centre in South India due to COVID-19- pandemic related national lockdown. *Indian J Ophthalmol.* 2021; 69(12):3643-3647.
7. Limbo B, Jha HC. Intraoperative complications of high volume sutureless cataract surgery in Nepal: a prospective study. *Kathmandu University Medical Journal.* 2014; 12(3):194-197.
8. Venkatesh R, Muralikrishnan R, Balent LC, Prakash SK, Prajna NV. Outcomes of high volume cataract surgeries in a developing country. *British Journal of Ophthalmology.* 2005; 89(9):1079-1083.
9. Sinha U, Chanchlani M, Singh SP, Chanchlani R. Barriers responsible for delayed utilisation of cataract surgery: an eye camp study from central India. *J of Evolution of Med and Dental Sci.* 2014; 3(11):2873-79.
10. Bourne R, Steinmetz JD, Flaxman S, Briant PS, Taylor HR, Resnikoff S, Casson RJ, Abdoli A, Abu-Gharbieh E, Afshin A, Ahmadieh H. Trends in prevalence of blindness and distance and near vision impairment over 30 years: an analysis for the Global Burden of Disease Study. *The Lancet Global Health.* 2021; 9(2):e130-143.
11. Cheng K, Anderson M, Velissaris S, Moreton RBR, Al-Mansour A, Sanders R et al. Cataract risk stratification and prioritisation protocol in the COVID-19 era. *BMC Health Services Research* [Internet]. 2021; 21(1). Available: <https://doi.org/10.1186/s12913-021-06165-1>
12. Wetarini K, Agrasidi PA, Kartiningsih IA, Dwipayani NM, Prahesthy HP. Visual outcomes following small incision cataract surgery (SICS) in Wangaya Hospital, Bali, Indonesia. *European J of Med and Health Sci.* 2020; 2(2).
13. Khandekar RB, Jain BK, Sudhan AK, Pandey KP: Visual acuity at 6 weeks after small incision cataract surgery and role of audit in predicting visual acuity. *Eur J Ophthalmol.* 2010; 20:345-352.
14. Mishra D, Singh H, Gogate P, Bhushan P, Singh MK, Srivastav T, Gogate B, Gaur S. Prevalence of incidental and total human immunodeficiency virus, hepatitis B and hepatitis C seropositivity among patients posted for cataract surgery at a tertiary care center in India. *Indian Journal of Ophthalmology.* 2022; 70(2):400-404.
15. Muralikrishnan J, Christy JS, Srinivasan K, Subburaman GB, Shukla AG, Venkatesh R, Ravilla TD. Access to eye care during the COVID-19 pandemic, India. *Bulletin of the World Health Organization.* 2022; 100(2):135.
16. Segers MH, Behndig A, van den Biggelaar FJ, Brocato L, Henry YP, Nuijts RM, Rosen P, Tassignon MJ, Young D, Stenevi U, Lundström M. Risk factors for posterior capsule rupture in cataract surgery as reflected in the European Registry of Quality Outcomes for Cataract and Refractive Surgery. *J of Cataract & Refractive Surgery.* 2022; 48(1):51-55.
17. McKellar MJ, Optom B, Elder MJ, Ganley JP. The early complications of cataract surgery: Is routine review of patients 1 week after cataract extraction necessary?. *Evidence-Based Eye Care.* 2002; 3(1):22-23.
18. Sridhar U, Tripathy K. Lens-Induced Inflammation. [Updated 2023 Aug 25]. In: StatPearls [Internet]. Treasure Island (FL): StatPearls Publishing. 2023 Jan-. Available from: <https://www.ncbi.nlm.nih.gov/books/NBK576439/>
19. Das S, Shergill S. Cataract surgery, their post-operative analysis, and a comparison of phacoemulsification and manual small-incision cataract surgery at a tertiary care hospital: A retrospective study. *Med J Dr DY Patil Vidyapeeth.* 2023; 16(1):80-84.
20. Madhani CH, Trivedi KY, Bhagat PR. Global preferred practice patterns in manual small incision cataract surgery. *Global J of Cataract Surgery and Research in Ophthalmology.* 2022; 1(1):4-9.

Cite this article as: Mudho RR, Sao P, Mudhol R, Biradar S, Vallabha K, Ijeri R and Sankolli N. The analysis of visual outcome and complications in camp patients undergoing manual small incision cataract surgery during COVID-19 period. *Al Ameen J Med Sci* 2024; 17(1): 85-89.

This is an open access article distributed under the terms of the Creative Commons Attribution-Non Commercial (CC BY-NC 4.0) License, which allows others to remix, adapt and build upon this work non-commercially, as long as the author is credited and the new creations are licensed under the identical terms.

*All correspondences to: Dr. Rekha R. Mudhol, Professor and Head, Department of Ophthalmology, Shri B.M. Patil Medical College, Hospital and Research Centre, Bangaramma Sajjan Campus, Solapur Road, Vijayapura-586103, Karnataka, India. E-mail: rekha.mudhol@gmail.com